JOBNAME: pho 26#12 2004 PAGE: 1 OUTPUT: Thu November 25 11:52:19 2004
lww/pho/90330/04-100R2

Effective Use of High-Dose Chemotherapy and Autologous Stem Cell Rescue for Relapsed Adult Wilms' Tumor and a Novel Alteration in Intron 1 of the *WT1* Gene

Ralf Ulrich Trappe, MD, Hanno Riess, MD,* Frank Lippek, MD,† Michail Plotkin, MD,‡ Valerie Schumacher, PhD,§ Brigitte Royer-Pokora, PhD,§ Bert Hildebrandt, MD,* Johannes Zuber, MD,* Markus Y. Mapara, MD,* Stephan Oertel, MD,* and Bernd Dörken, MD**

Summary: Adult Wilms' tumor (AWT) is a very rare and aggressive malignancy, and little information is available on effective therapy in adults. Although mutations in *WT1* have been found in 10% to 15% of childhood Wilms' tumor patients, to date *WT1* mutations in AWT patients have not been described. The authors describe a 47-year-old man with relapsed AWT and a novel germline alteration in intron 1 of *WT1*: IVS1-6 C→A. This alteration may reduce the splicing efficiency for exon 2 and possibly results in exon skipping. The effective salvage chemotherapy contained ifosfamide, carboplatin, and etoposide and was followed by a high-dose chemotherapy that contained melphalan, carboplatin, and etoposide. Both chemotherapy regimens showed moderate treatment-related toxicity. This report is the first that indicates that adult nephroblastoma patients also may carry *WT1* germline mutations.

Key Words: Wilms', tumor, nephroblastoma, relapse, high-dose chemotherapy, autologous stem cell rescue, *WT1* mutation

(*J Pediatr Hematol Oncol* 2004;26:820–823)

Wilms' tumor is the most common abdominal malignancy in children but is extremely rare in adults. Like other pediatric malignancies, Wilms' tumor has a poorer prognosis in adults than in children, resulting in 3-year survival rates of up to 67% in combined modality protocols as reported by the National Wilms Tumor Study (NWTS) in 1990.[1] Despite established treatment protocols for all stages of disease in children, little information is available on effective therapy in adults, especially in case of tumor relapse. Altogether, fewer than 240 cases of adult Wilms' tumor (AWT) have been reported in the literature, and some of these are now known to have been rhabdoid tumors, clear cell sarcomas, or other renal neoplasms.[2] Five cases of successful therapy for relapsed AWT have been published to date.[3–6] In contrast, there is a large amount of data with long-term follow-up concerning children's cases. About 90% of patients with childhood Wilms' tumor can now be cured, and reported estimates of long-term survival after relapse are about 50% to 60%. Patients who initially had unfavorable-histology disease, advanced disease, short duration of remission, or abdominal (lymph node) recurrence within the prior field of irradiation or who underwent upfront multidrug chemotherapy have an impaired survival rate.[7] Despite high treatment-related toxicity in dose-intensive chemotherapy, high-dose therapy has proven effective in the treatment of recurrent Wilms' tumor,[8] even though it is unknown whether high-dose therapy is superior to conventional-dose chemotherapy.

Although there is much genetic heterogeneity in Wilms' tumor initiation, in about 5% of Wilms' tumors intragenic *WT1* mutations have been found. To date no data about the penetrance of *WT1* germline mutations and the risk of Wilms' tumor conferred by these mutations are available. However, these patients should be followed carefully.

CASE REPORT

We describe a 47-year-old man who had a 2- to 3-month history of persistent right lower back pain at the time of diagnosis. A computed tomography (CT) scan of his abdomen revealed a tumor replacing the right kidney measuring 10 × 15 cm with multiple regional and paracaval lymph node metastases (Fig. 1A). The patient initially was treated with tumor nephrectomy and para-aortal lymphadenectomy under the suspicion of a renal cell carcinoma of his right kidney in April 2001. Tumor resection was with macroscopic residual disease (Fig. 1B). The patient's medical history prior to tumor manifestation was uneventful, besides right-sided orchiectomy in childhood for unknown reasons. Staging examinations included a bone scan and brain and chest CT scans; none revealed abnormalities. Pathologic examination of the tumor showed the typical triphasic histomorphology of a Wilms' tumor with broad regions of low differentiation, regions containing tubular structures, and mesenchymal differentiated regions (Fig. 2A). Immunohistochemically, the tumor cells were positive for CD56 and WT1, further proof for the diagnosis of a nephroblastoma (Fig. 2A). To analyze for *WT1* germline mutations, DNA was prepared from the patient's peripheral blood lymphocytes. *WT1* exons and exon/intron boundaries were amplified by PCR and subjected to SSCP analysis.[9] Exon 2 revealed

Received for publication April 4, 2004; accepted September 27, 2004.
From the *Department of Hematology and Oncology, Charité University Hospital Berlin, Campus Virchow Klinikum, Berlin, Germany; †Institute of Pathology, Charité University Hospital Berlin, Campus Berlin-Mitte, Berlin, Germany; ‡Radiology Departments, Charité University Hospital Berlin, Campus Virchow Klinikum, Berlin, Germany; and §Institute of Human Genetics and Anthropology, Heinrich Heine University Düsseldorf, Düsseldorf, Germany.
Reprints: Dr. R. Trappe, Department of Hematology and Oncology, Charité, Campus Virchow-Klinikum, Augustenburger Platz 1, D-13353 Berlin, Germany (e-mail: ralf_ulrich.trappe@charite.de).
Copyright © 2004 by Lippincott Williams & Wilkins

JOBNAME: pho 26#12 2004 PAGE: 2 OUTPUT: Thu November 25 11:52:20 2004
lww/pho/90330/04-100R2

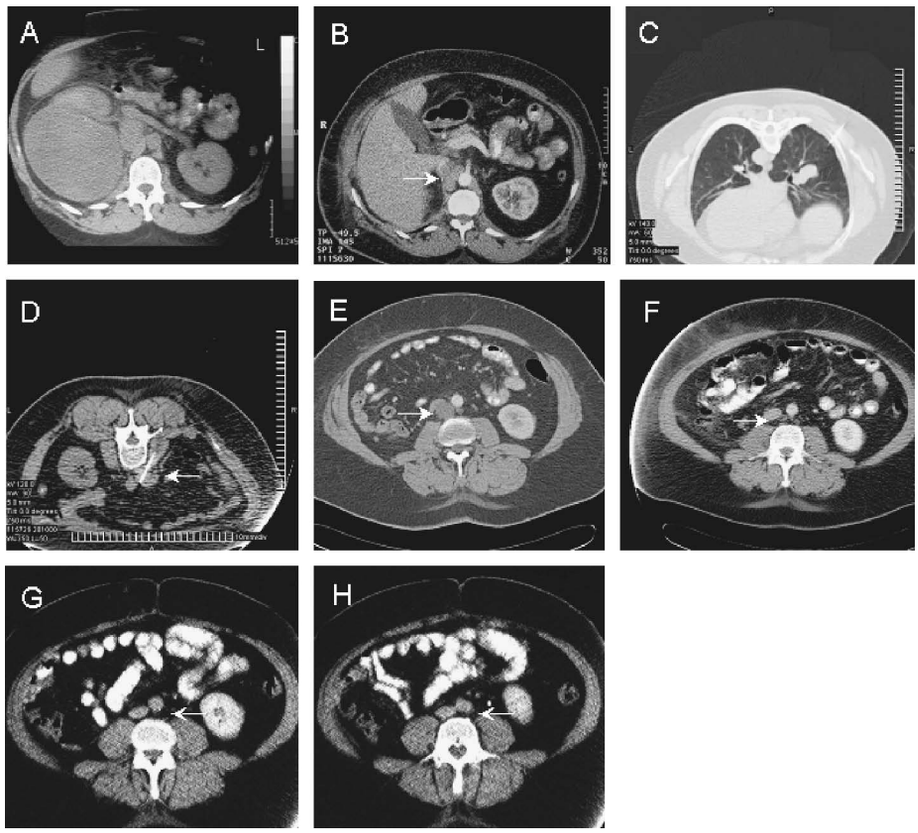

FIGURE 1. Clinical course. A, In April 2001 abdominal CT scans revealed a large intra-abdominal tumor mass involving the right kidney. B, Postoperative status: tumor residues were present adjacent to the right diaphragmatic crus, showing macroscopic residual disease after tumor resection. C, CT-guided biopsy of a pulmonary tumor mass in the right upper lobe in June 2001 (first relapse). D, CT-guided biopsy of an aortointercaval lymph node manifestation in December 2002 (second relapse). E, In January 2003 abdominal CT scans before salvage chemotherapy showed the aortointercaval lymph node 3 cm in diameter with compression of the inferior vena cava. F, Abdominal CT scans after finishing two cycles of salvage chemotherapy revealed radiomorphologic complete remission. G and H, CT scans showing ongoing complete remission in March 2004.

an aberrant migrating PCR product that was sequenced. A heterozygous alteration in position -6 of intron 1 was found—IVS1-6 C→A (tc<u>c</u>cgcagGT≫ tc<u>a</u>cgcagGT)—that has never been described before (Fig. 2B).

Complete remission of postoperative residues was induced by a 6-week chemotherapy regimen of actinomycin D, vincristine, and doxorubicin (Adriamycin) and was followed by adjuvant radiochemotherapy according to stage III disease. In adjuvant radiotherapy, irradiation doses were 16 Gy for the right abdomen, 30 Gy for the para-aortal region, and 36 Gy for the tumor bed region. Adjuvant chemotherapy consisted of actinomycin D, vincristine, and doxorubicin (Adriamycin) for a second time and was administered for a period of 28 weeks according to the German SIOP93-01/GPOH study protocol for pediatric Wilms' tumors. Final staging showed no evidence of disease in March 2002, but the patient relapsed with a single pulmonary metastasis 3 months later (Fig. 1C) and with a lymph node metastasis within the irradiated para-aortal region 9 months later (December 2002, Fig. 1D). While the pulmonary metastasis was resected entirely (July 2002, see Fig. 2A), a complete remission of the lymph node relapse was induced by two cycles of systemic salvage chemotherapy containing ifosfamide, carboplatin, and etoposide, administered from January 2003 to February 2003 (Figs. 1E and 1F). Relative doses were 3,000 mg/m^2 for ifosfamide, 200 mg/m^2 for carboplatin, and 100 mg/m^2 for etoposide given on days 1 to 3. Peripheral blood stem cells were mobilized with G-CSF (5 μg/kg) after the first cycle. For final consolidation, dose escalation using high-dose chemotherapy containing melphalan 60 mg/m^2 (days 1–3), carboplatin AUC4 (days 4–8), and etoposide 200 mg/m^2 (days 4–8) was given in May 2003. After autologous peripheral blood stem cell transplantation (3.1 × 10^6 CD34$^+$ cells/kg), rapid engraftment occurred, and on day +11 and +15, his neutrophil count was more than 1.0 × 10^9/L and his platelet count was more than 20 × 10^9/L. Treatment-related toxicity after high-dose chemotherapy included oral mucositis (WHO III°), neutropenic fever, acute non-dialysis-requiring renal failure, and transitory hyperbilirubinemia. Twelve months after high-dose chemotherapy and 17 months after relapse the patient remains well and disease-free as shown by CT scan examinations in March 2004 (Figs. 1G and 1H).

DISCUSSION

There are three similar reports illustrating the effectiveness of salvage chemotherapy combined with high-dose therapy in relapsed AWT. The first report describes a pararectal AWT relapse treated by surgery, adjuvant high-dose chemotherapy, and radiation therapy; this patient was reported to be alive and disease-free 3.5 years after bone marrow transplantation.[6] The second report describes a patient who had relapsed twice: after initial adjuvant treatment and after treatment with high-dose doxorubicin; the patient was treated successfully with cisplatin and etoposide.[5] The third report illustrates successful high-dose chemotherapy in a 23-year-old man with a pulmonary AWT relapse 28 months after resection of a pulmonary metastasis.[3] In summary, salvage chemotherapy protocols using high-dose chemotherapy with autologous stem cell rescue are effective in relapsed AWT and may lead to long-lasting tumor control. However, local resection strategies also have proven to be effective in disease control—for 28 months in the patient described by Petty et al[3] and for 6 months in the patient described here. Due to the rarity of the disease

© 2004 Lippincott Williams & Wilkins

JOBNAME: pho 26#12 2004 PAGE: 3 OUTPUT: Thu November 25 11:52:23 2004
lww/pho/90330/04-100R2

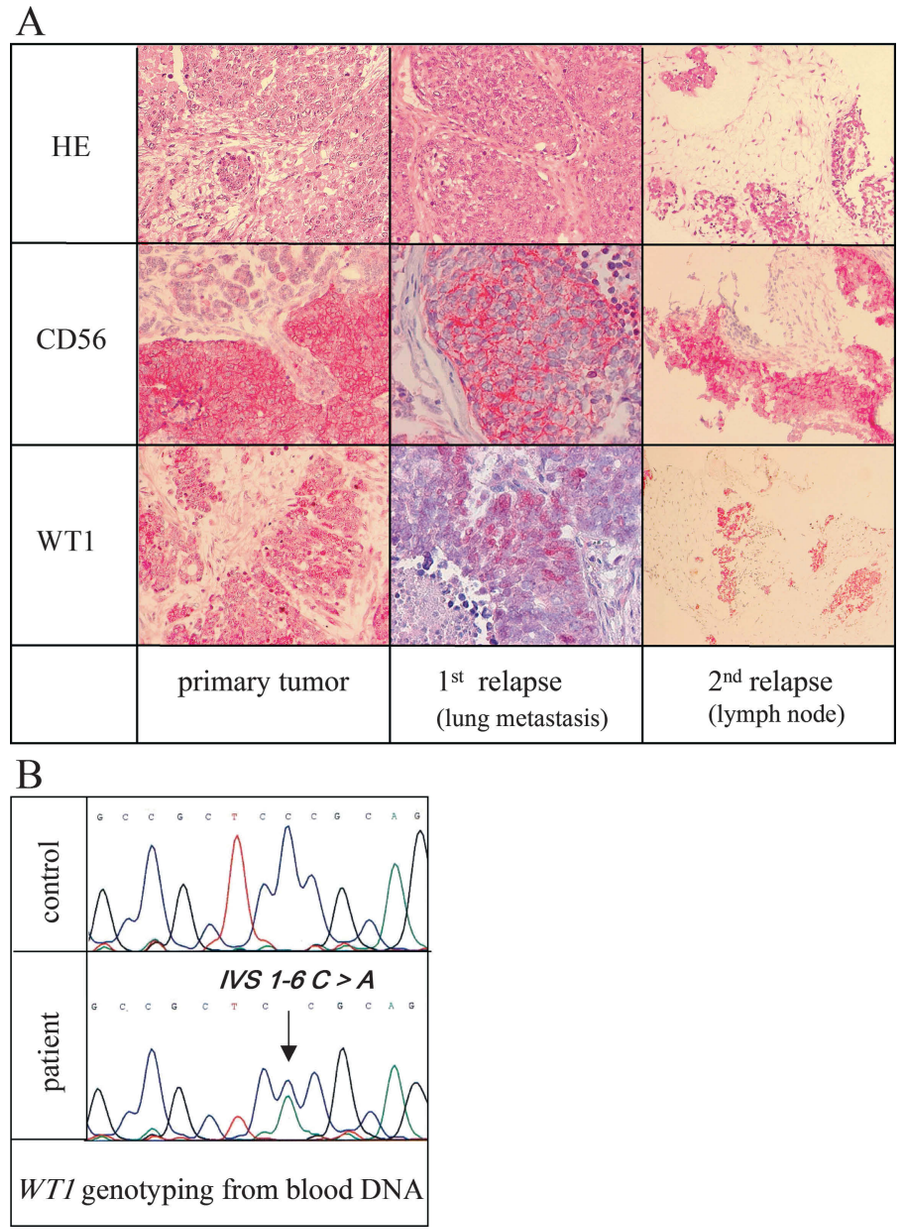

FIGURE 2. Tumor characterization. A, Tumor sections from diagnosis and first and second relapse. Original magnification ×200. H&E staining: the tumor sections show a triphasic histomorphology of a Wilms' tumor with a mixture of tubular, mesenchymal, and stromal components. Pulmonal metastases (first relapse, middle picture) and lymph node metastases (second relapse, right picture) show tumor tissues mainly composed of stromal components. CD56 staining: immunostaining using a CD56 antibody, CD56/ NCAM-1 Ab-2 (123C3.D5) (NeoMarkers, Laboratory Vision Corp.) in a 1:100 dilution. WT1 staining: WT1 staining using a polyclonal WT1 antibody raised against a peptide mapping at the carboxy terminus of the human WT1 protein, WT1 (C-19): sc192 (Santa Cruz) in a 1:200 dilution. All tissue samples show high expression levels of CD56 and WT1, proving their common origin and classification as Wilms' tumor. B, *WT1* sequence analysis of DNA prepared from peripheral white blood cells. The upper panel shows the wild-type sequence of human *WT-1* intron 1 (position –1 to –13). The lower panel shows the patient's *WT1* sequence and reveals a heterozygous alteration: IVS1-6 C→A. The nucleotide change IVS1-6 C→A is predicted to reduce exon/intron splicing efficiency.

and the tendency for delayed relapse, a further exploration of therapy will require an international intergroup trial.

Our patient showed a *WT1* germline alteration: IVS1-6 C→A. Stromal-predominant tumors and to a lesser extent mixed triphasic tumors of childhood WT patients were shown to be specifically correlated with *WT1* mutations in 62% (13/21) and in 25% (4/16) of cases, respectively. *WT1* mutations were present in the patients' germline in 82%,[9] and almost all male patients with *WT1* germline mutations revealed genitourinary malformation, including maldescended testis, hypospadias, cryptorchidism, unilateral testicular aplasia, ambiguous external genitalia or WAGR syndrome.[9] The patient described here had a mixed triphasic tumor and his clinical history included right-sided orchiectomy in childhood for unknown reasons. Using the algorithm available from the University of California, Berkeley web site (http//www.fruitfly.org/seq_tools/splice.html), the alteration IVS1-6 C→A reduces the splicing efficiency from 0.96 to 0.77. Splice site mutations causing exon skipping of *WT1* in Wilms' tumor patients have been described.[10] Regular alternative splicing of intron 9 shows a calculated splicing efficiency of 0.94 for the first splice site and 0.76 for the alternative site, resulting in two different transcripts (+KTS/-KTS). Mutations of the second splice site are associated with Frasier syndrome, reducing the splicing probability to 0.12 to 0.55, depending on the specific mutation.[11] The alteration IVS1-6 C→A may lead to a reduced efficiency for splicing and possibly to exon skipping, resulting in an additional *WT1* transcript devoid of exon 2. In the human

© 2004 Lippincott Williams & Wilkins

Fig. 2 live 4/C

JOBNAME: pho 26#12 2004 PAGE: 4 OUTPUT: Thu November 25 11:52:59 2004
lww/pho/90330/04-100R2

Wilms' tumor cell line (RM1) a *WT1* splice variant was detected devoid of exon 2 sequences. This splicing alteration was also detected in varying amounts in some Wilms' tumors but not in normal kidney. Haber et al speculated that the production of this abnormal transcript might be a distinct mechanism for inactivating WT1 in Wilms' tumors.[12]

In summary, our report is the first that indicates that adult WT patients also may carry *WT1* germline mutations. There may be a distinct mechanism for inactivating WT1 in these Wilms' tumors.

REFERENCES

1. Arrigo S, Beckwith JB, Sharples K, et al. Better survival after combined modality care for adults with Wilms' tumor. A report from the National Wilms' Tumor Study. *Cancer*. 1990;66:827–830.
2. Kilton L, Matthews MJ, Cohen MH. Adult Wilms tumor: a report of prolonged survival and review of literature. *J Urol*. 1980;124:1–5.
3. Petty R, Culligan D, Bissett D. Successful salvage of relapsed adults Wilms' tumour with high-dose chemotherapy and autologous peripheral blood stem cell rescue. *Clin Oncol (R Coll Radiol)*. 2002;14:329.
4. Tawil A, Cox JN, Roth AD, et al. Wilms' tumor in the adult: report of a case and review of the literature. *Pathol Res Pract*. 1999;195:105–111.
5. Abratt RP, du Preez HM, Kaschula R. Adult Wilms ' tumor. Cisplatin and etoposide for relapse after adjuvant chemotherapy. *Cancer*. 1990;65:890–892.
6. Hupperets PS, Havenith MG, Blijham GH. Recurrent adult nephroblastoma. Long-term remission after surgery plus adjuvant high-dose chemotherapy, radiation therapy, and allogeneic bone marrow transplantation. *Cancer*. 1992;69:2990–2992.
7. Dome JS, Liu T, Krasin M, et al. Improved survival for patients with recurrent Wilms tumor: the experience at St. Jude Children's Research Hospital. *J Pediatr Hematol Oncol*. 2002;24:192–198.
8. Pein F, Michon J, Valteau-Couanet D, et al. High-dose melphalan, etoposide, and carboplatin followed by autologous stem-cell rescue in pediatric high-risk recurrent Wilms' tumor: a French Society of Pediatric Oncology study. *J Clin Oncol*. 1998;16:3295–3301.
9. Schumacher V, Schneider S, Figge A, et al. Correlation of germ-line mutations and two-hit inactivation of the WT1 gene with Wilms tumors of stromal-predominant histology. *Proc Natl Acad Sci USA*. 1997;94:3972–3977.
10. Schneider S, Wildhardt G, Ludwig R, et al. Exon skipping due to a mutation in a donor splice site in the WT-1 gene is associated with Wilms' tumor and severe genital malformations. *Hum Genet*. 1993;91:599–604.
11. Barbaux S, Niaudet P, Gubler MC, et al. Donor splice-site mutations in WT1 are responsible for Frasier syndrome. *Nat Genet*. 1997;17:467–470.
12. Haber DA, Park S, Maheswaran S, et al. WT1-mediated growth suppression of Wilms tumor cells expressing a WT1 splicing variant. *Science*. 1993;262:2057–2059.

© *2004 Lippincott Williams & Wilkins*